Digestive system (GIT-207)

Histology

Stomach

Ass.Prof. Dr. Safaa Said

Department of Histology &Cell Biology

Merit University

Stomach:

- The stomach is a dilated segment of the digestive tract. It is made up of four major regions: the cardia, fundus, body, and pylorus.
- The cardia is a narrow transitional zone between the esophagus and the stomach;
- the pylorus is the funnel-shaped region. Both these regions are primarily involved with mucus production and are histogically similar.
- The fundus and body regions are identical in structure
- The mucosa and submucosa of the empty stomach have large, longitudinally directed folds called rugae, which flatten when the stomach fills with food.

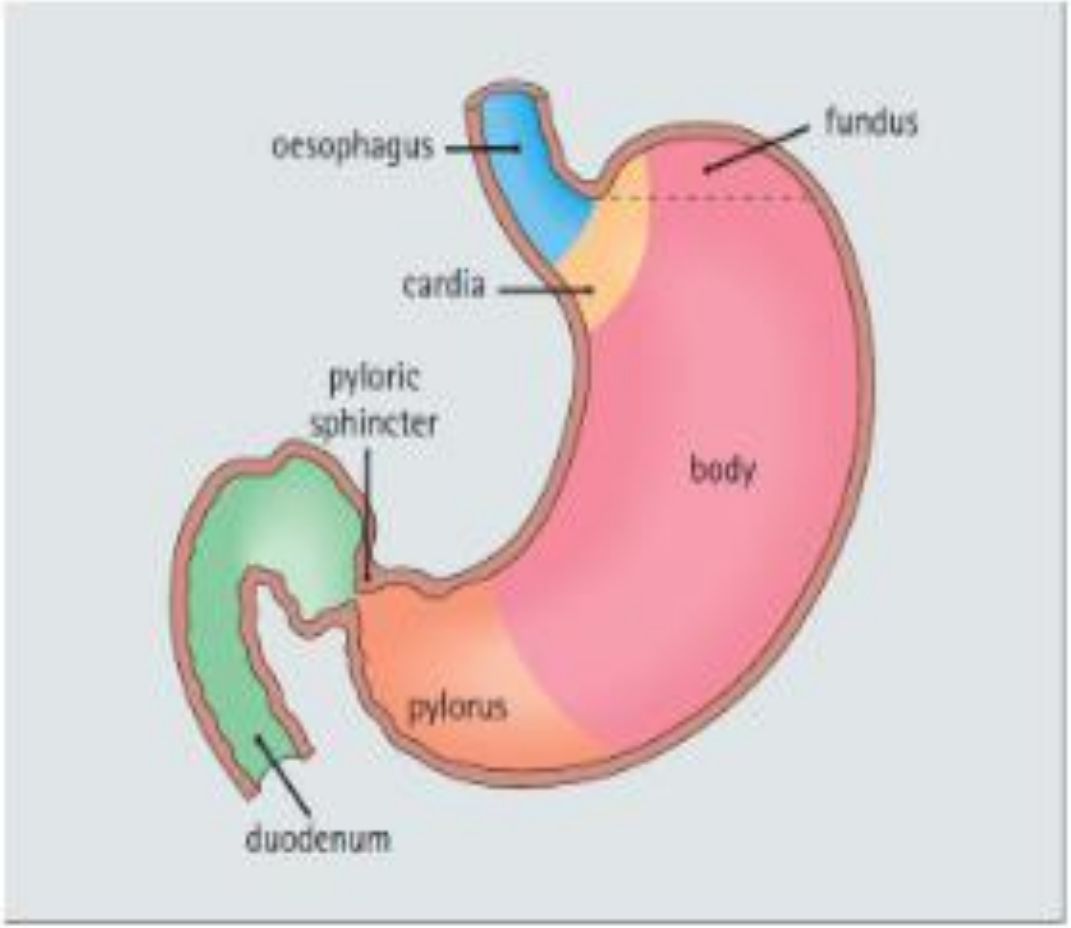

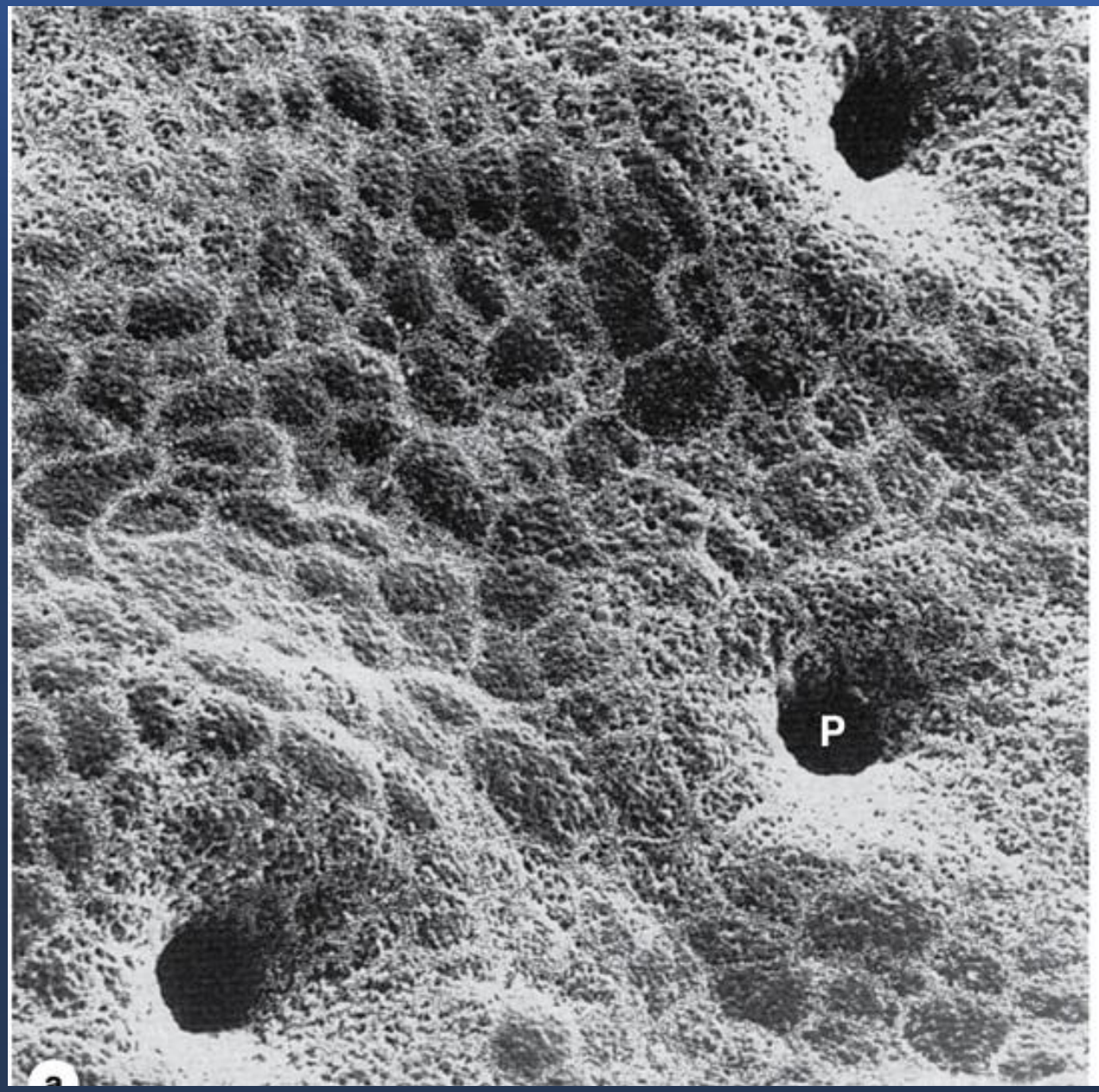
P
a

P
P
b

The stomach is lined by simple columnar surface epithelial cells that invaginates into the lamina propria, forming gastric pits.

Gastric pits leads to tubular glands that extend through the full thickness of the lamina propria.

In the cardiac and pyloric regions, the epithelium lining the gland is mainly mucus-secreting cells. However, glands of the main portion of the stomach (the corpus or fundus) possess five types of epithelial cells, each having distinctive functions.

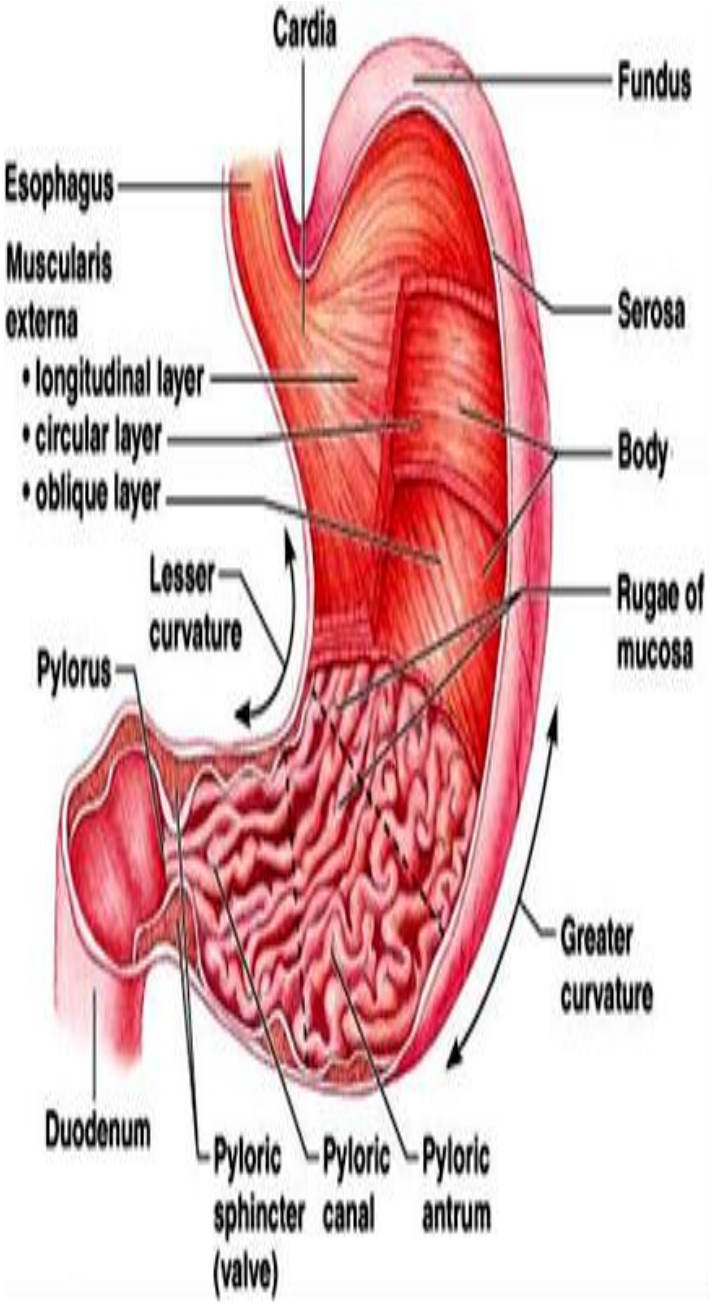

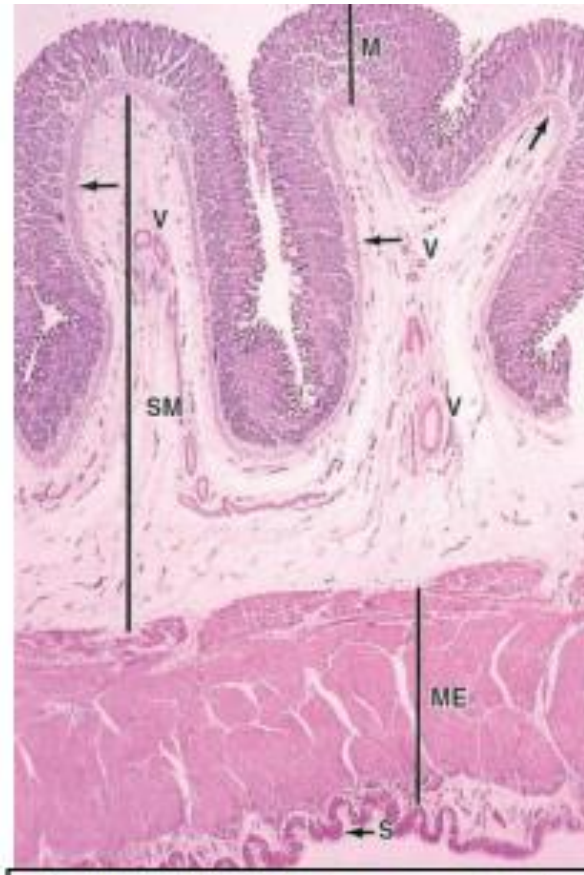

Two rugae (folds) cut transversely and consist of mucosa and submucosa. Note; the 4 layers that form the stomach wall. **M** mucosa, **SM** submucosa, **ME** muscularis externa, **S** serosa.

Mucosa:

The surface mucus cells Line the lumen of the stomach and ga

- Columnar cells with basal nuclei and pale staining cytoplasm, apical short microvilli covered with glycocalyx.
- The apical cytoplasm contains mucinogen granules.
- Their lateral cell membranes form tight junctions with neighboring cells.
- Their nuclei are basal while the cell organelles are supranu

o Function; they secrete a thick, adherent and highly viscous mucous layer, which is rich in bicarbonate ions and protects the mucosa .

Lamina propria; a loose connective tissue surrounds the glands

Muscularis mucosa; a layer of smooth muscle

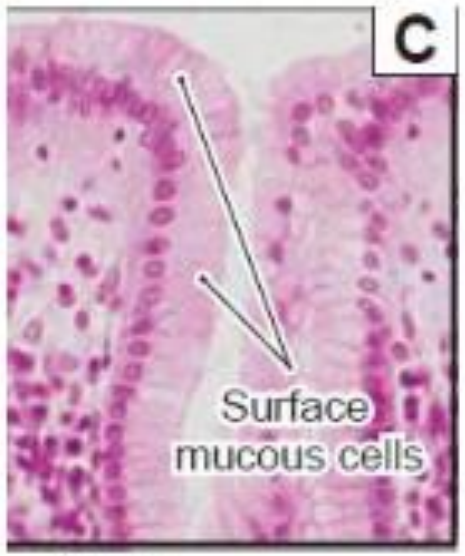

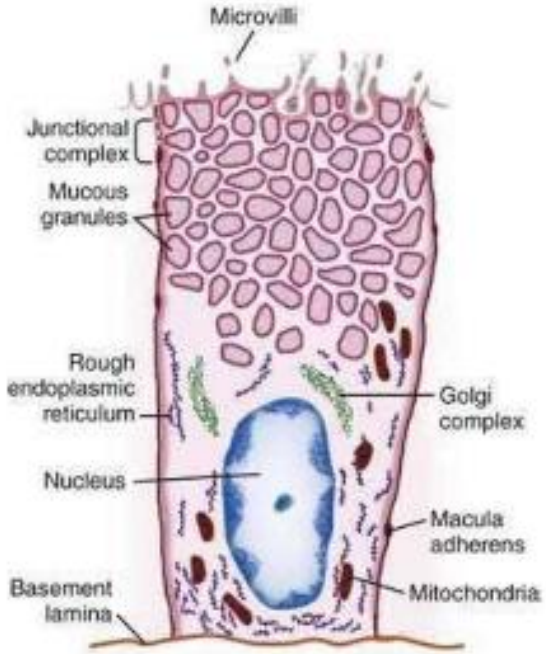

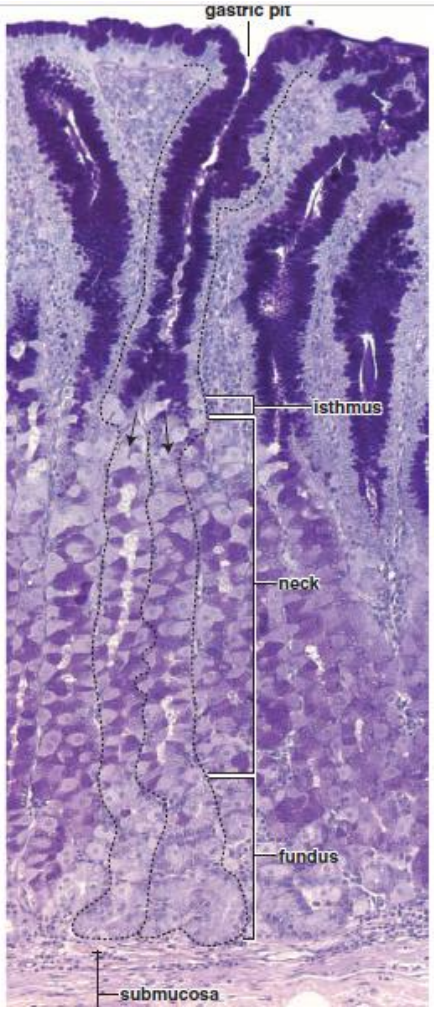
gastric pit
isthmus
neck
fundus
submucosa

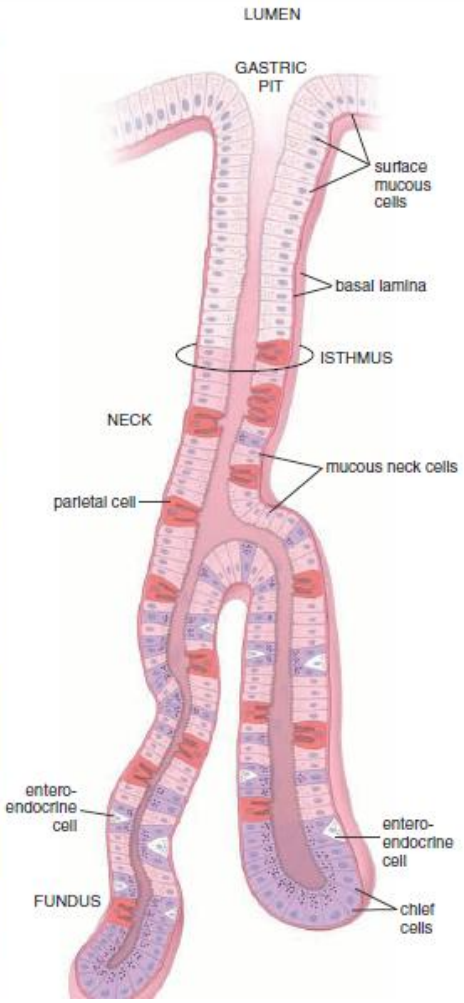
LUMEN
GASTRIC PIT
surface mucous cells
basal lamina
ISTHMUS
NECK
mucous neck cells
parietal cell
entero-endocrine cell
entero-endocrine cell
FUNDUS
chief cells

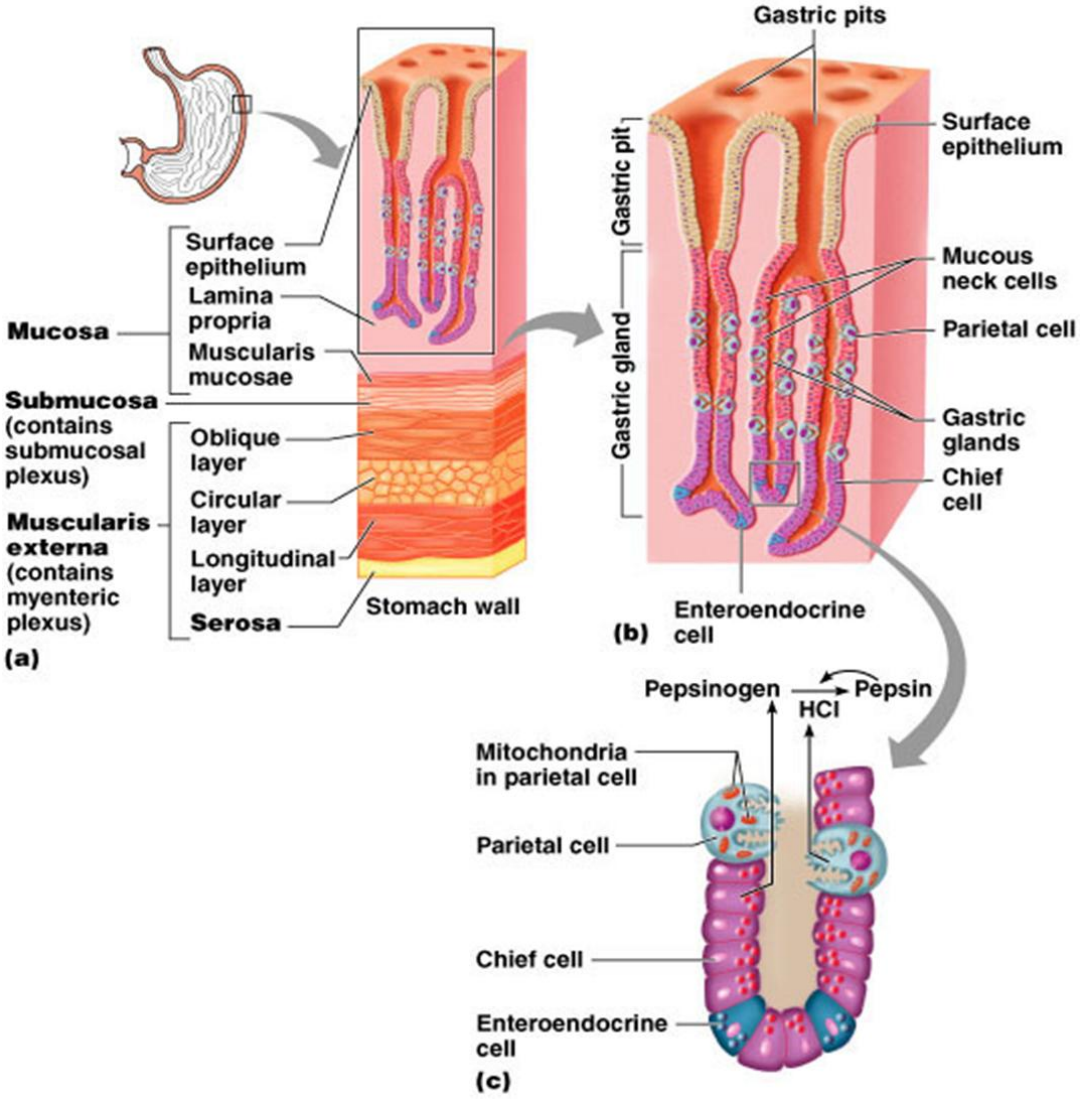
Gastric pits
Surface epithelium
Lamina propria
Muscularis mucosae
Mucosa
Submucosa (contains submucosal plexus)
Oblique layer
Circular layer
Longitudinal layer
Muscularis externa (contains myenteric plexus)
Serosa
Stomach wall
(a)
Gastric pit
Gastric gland
Mucous neck cells
Parietal cell
Gastric glands
Chief cell
Enteroendocrine cell
(b)
Pepsinogen
Pepsin
HCl
Mitochondria in parietal cell
Parietal cell
Chief cell
Enteroendocrine cell
(c)

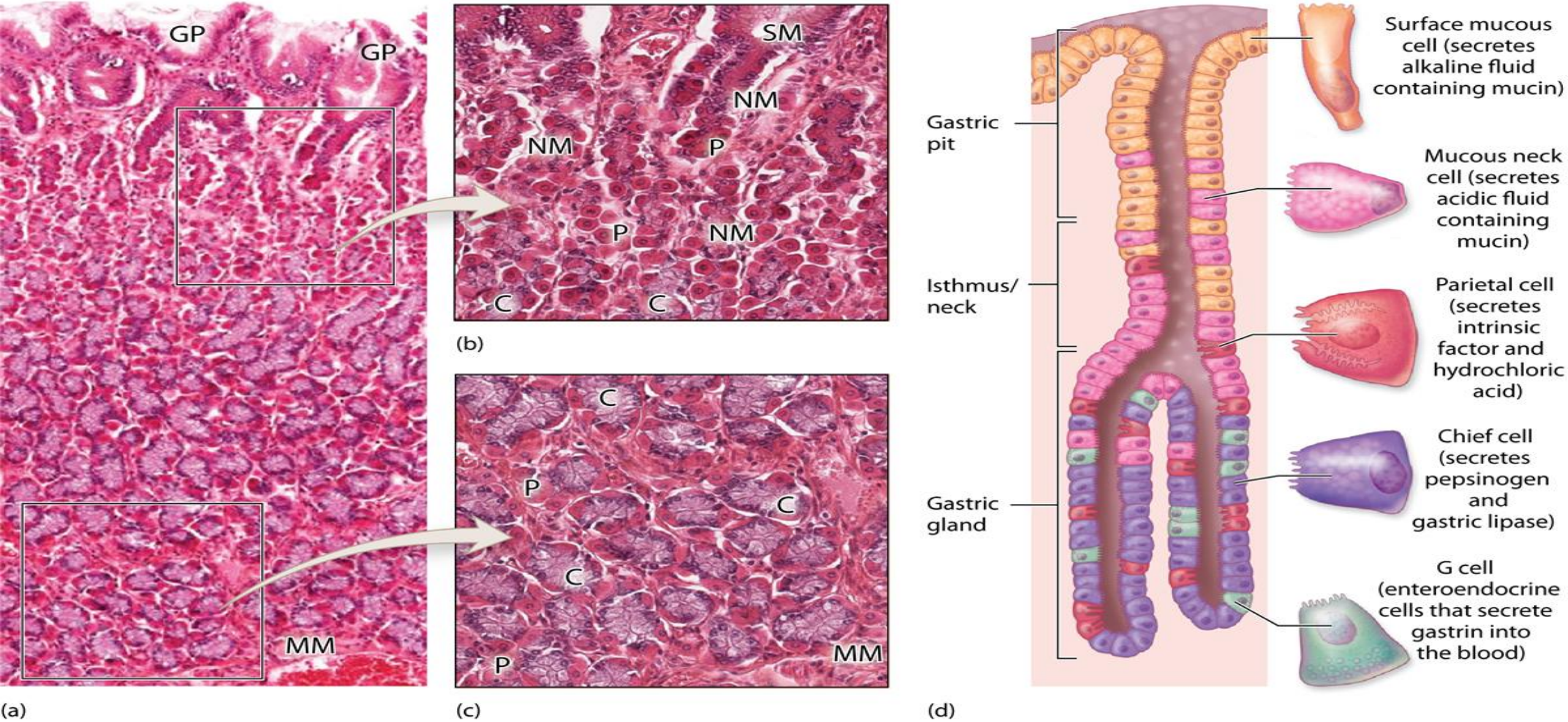
GP
GP
MM
(a)
SM
NM
NM
P
P
NM
C
C
(b)
C
P
C
C
P
MM
(c)
Gastric pit
Isthmus/ neck
Gastric gland
Surface mucous cell (secretes alkaline fluid containing mucin)
Mucous neck cell (secretes acidic fluid containing mucin)
Parietal cell (secretes intrinsic factor and hydrochloric acid)
Chief cell (secretes pepsinogen and gastric lipase)
G cell (enteroendocrine cells that secrete gastrin into the blood)
(d)

Figure 15-17

Fundus and body regions:

In the fundus and body, the gastric pits are short and the glands in these regions, also known as gastric (fundic) glands, fill most of the mucosa.

Each gland consists of an isthmus, which connects the gland to the base of a gastric pit; a neck; and a base.

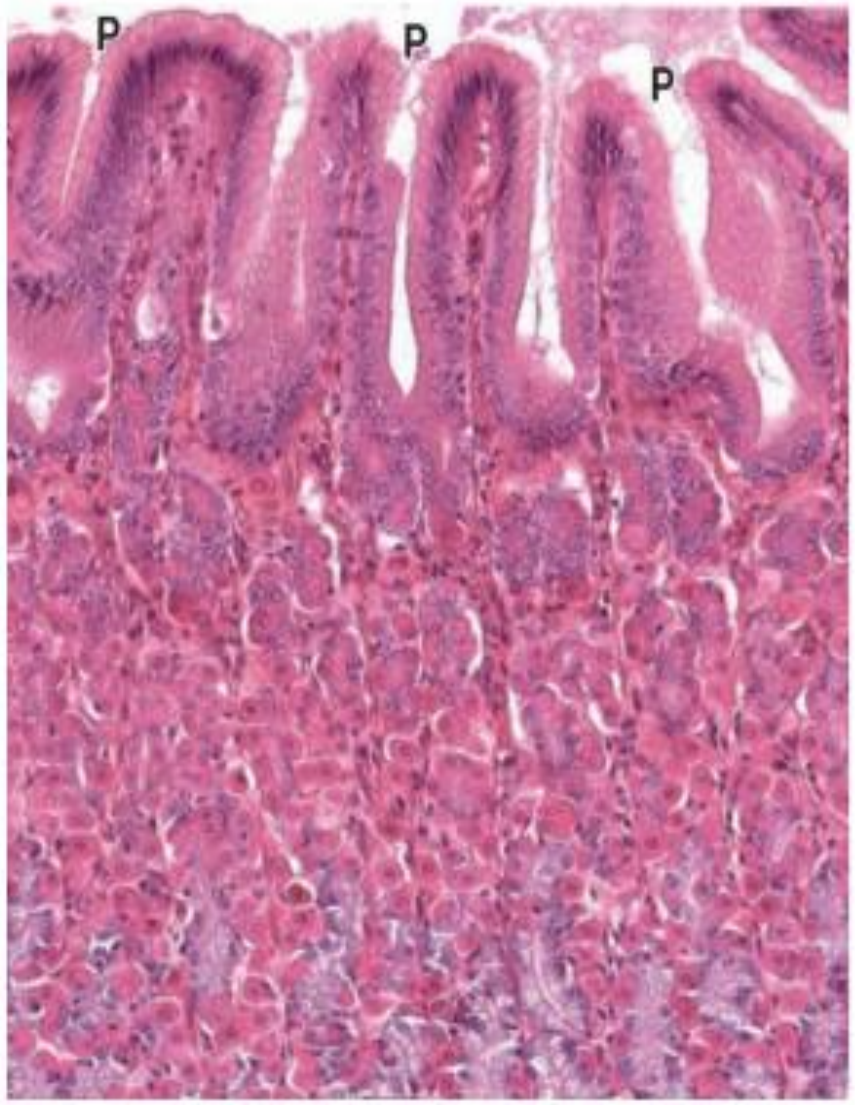

A- Fundic (or gastric) glands:

These are branched tubular glands. Five types of cells can be found within the gland:

1- Mucous neck cells are similar to the mucous lining cells but are shorter and produce a thinner alkaline mucous.

2- Stem cells are found in the isthmus of the gland; they divide and differentiate into the other cell types. The turn-over time for mucous cells is only 3-5 days compared to half a year for the parietal, chief and enteroendocrine cells.

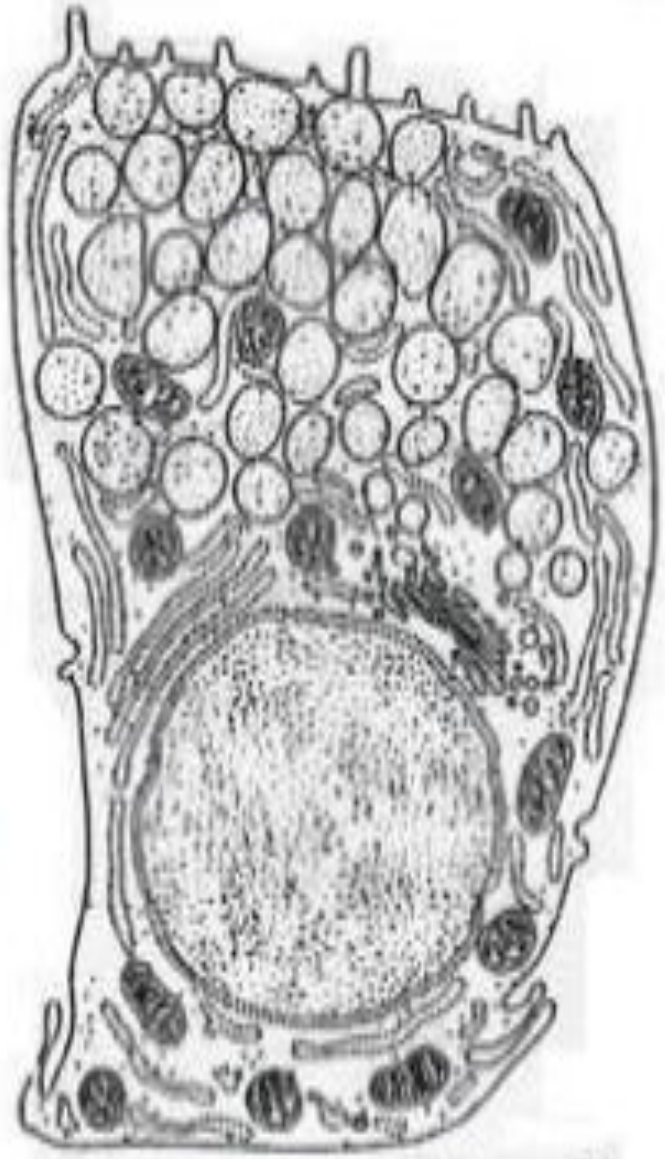

Mucous neck cell

3- The parietal cells

- **Function**

- Produce hydrochloric acid which serves in acid digestion, pepsin activation and as a bacteriostat. The acid is formed extra-cellularly .

-The cells produce intrinsic factor (glycoprotein) which is important in B12 absorption in the ileum.

LM; Found in the neck of the gland and appear histologically as large, round or pyramidal cells with a central nucleus and intensely eosinophilic cytoplasm.

EM;

- tubulovesicular system, deep circular nvaginations of the apical plasma membrane, forming intracellular canaliculi.
- The remaining cytoplasm is filled with mitochondria.
  - Inactive parietal cells shows increased tubulovesicular system and few microvilli
  - active parietal cell shows abundant microvilli (MV) and decreased tubulovesicular system.

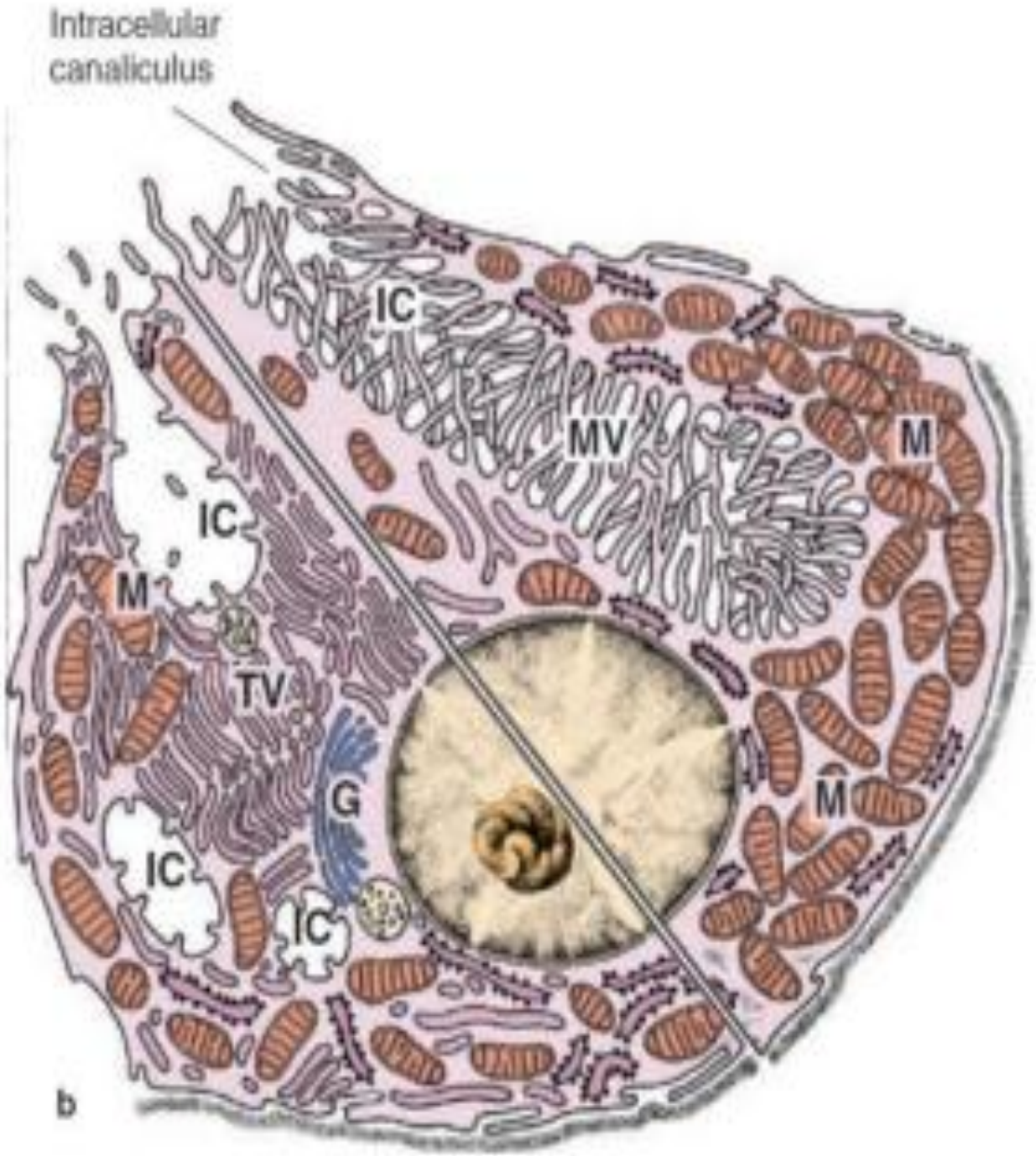

4. Chief (zymogen or peptic) cells:

- LM; small, columnar cells ,numerous in the lower half of the gastric glands with darkly stained cytoplasm.
- Their nuclei are basal.
- They have all the characteristics of protein-synthesizing and secreting cells.
- The cytoplasmic granules contain the inactive enzyme pepsinogen; rennin and gastric lipase

EM, Well developed Golgi.

- they have extensive rough ER and apical membrane-bound secretory vesicles(zymogen granules) near the lumen.
- Apical cell membrane has few short microvilli

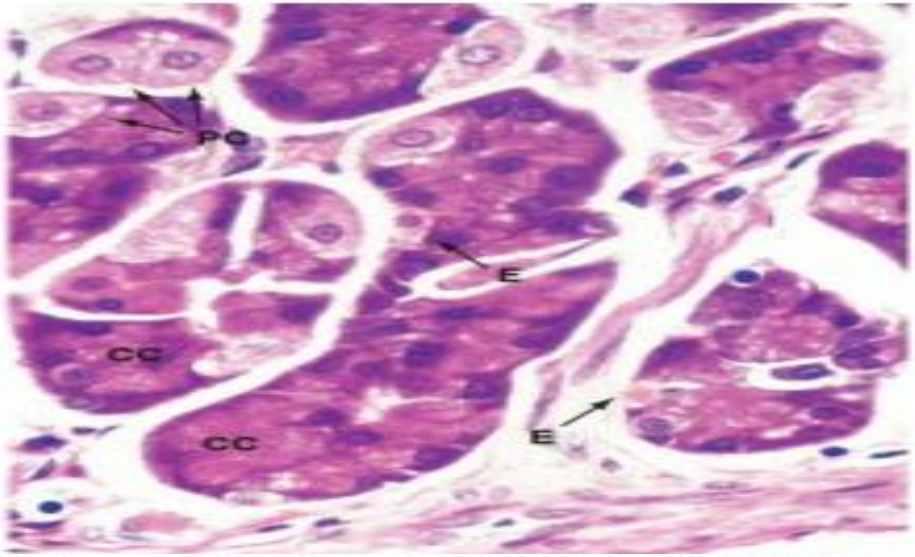

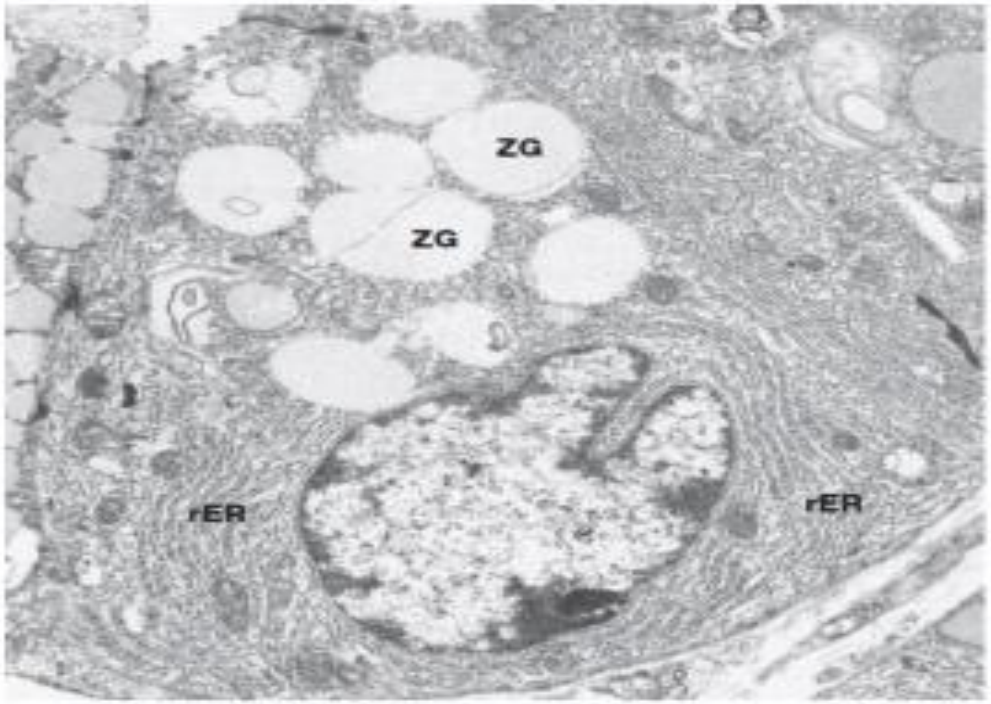

5. Enteroendocrine (DNES) cells.

- **By L.M.:** Can **not be detected by H&E stain**. Detected with **silver stain**, hence the name **argentaffin cells**. Appear as small cells **resting on the basal lamina.**

There are at least 12 different types of cells which produces ab **20 gastrointestinal hormones**. One type of these cells secretes **serotonin;** a second type of cells secretes **enteroglucagon**. Other cells produce gastrin, endorphin and encephalin.

Are of **two major categories**, open and closed.

- They are believed to be **chemosensory**,
- House many **small hormone-containing granules**, usually concentrated in **the basal cytoplasm**.
- Possess an abundance of **mitochondria and RER** and a moderately **well-developed Golgi complex**.

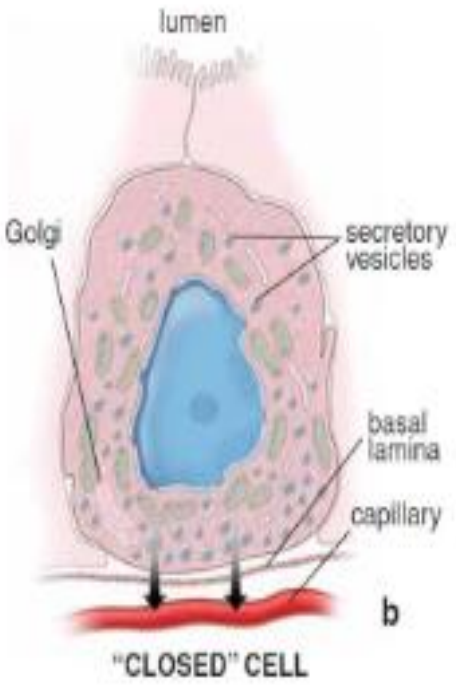

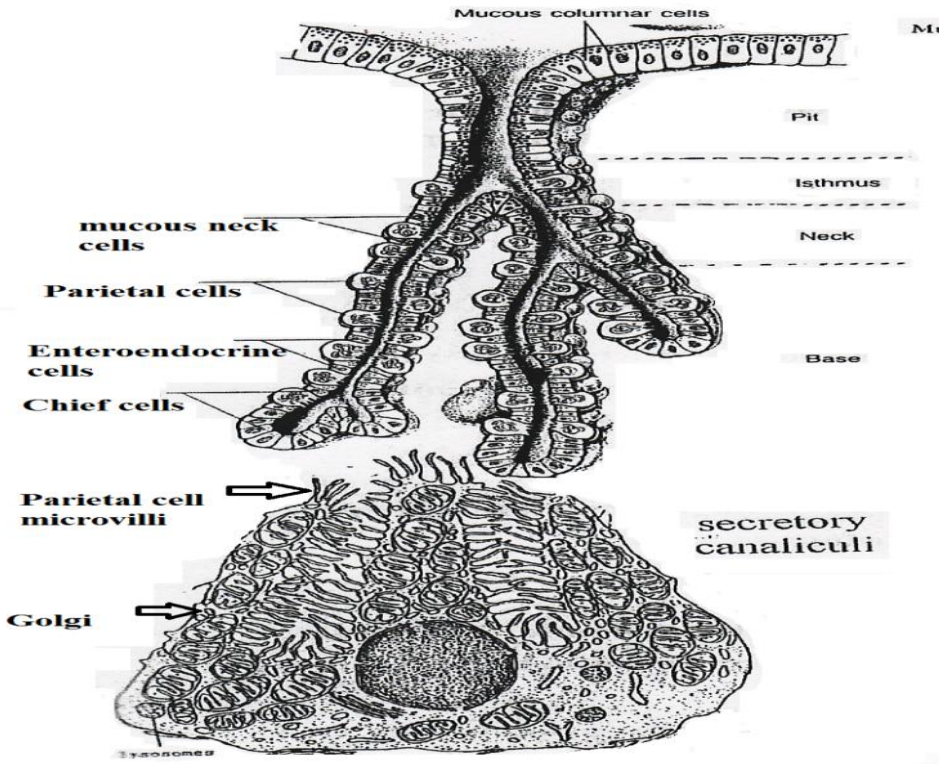

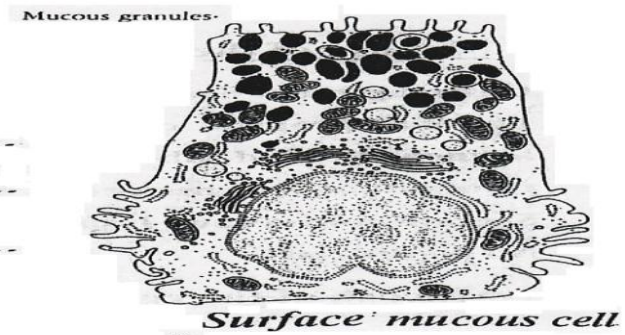

Surface mucous cell

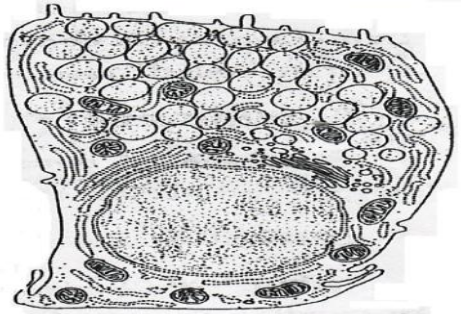

Mucous neck cell

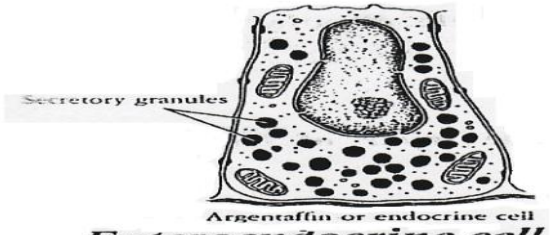

Enteroendocrine cell

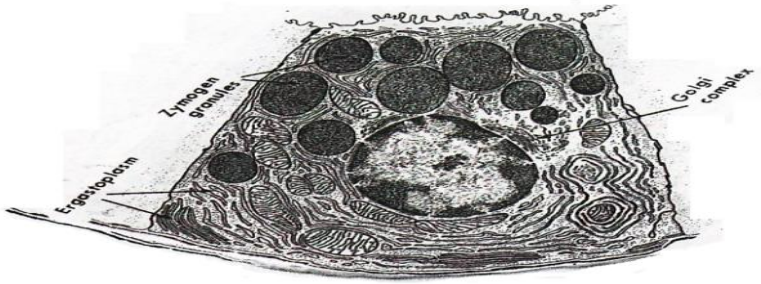

Peptic(Chief) cell

Cardiac region (cardia):

- Gastric pits are shallow.
- The mucosa has tubular, tortious and occasionally branched cardiac glands.
- Cardiac gland are lined with mucus-secreting cells and few Enteroendocrine cells.

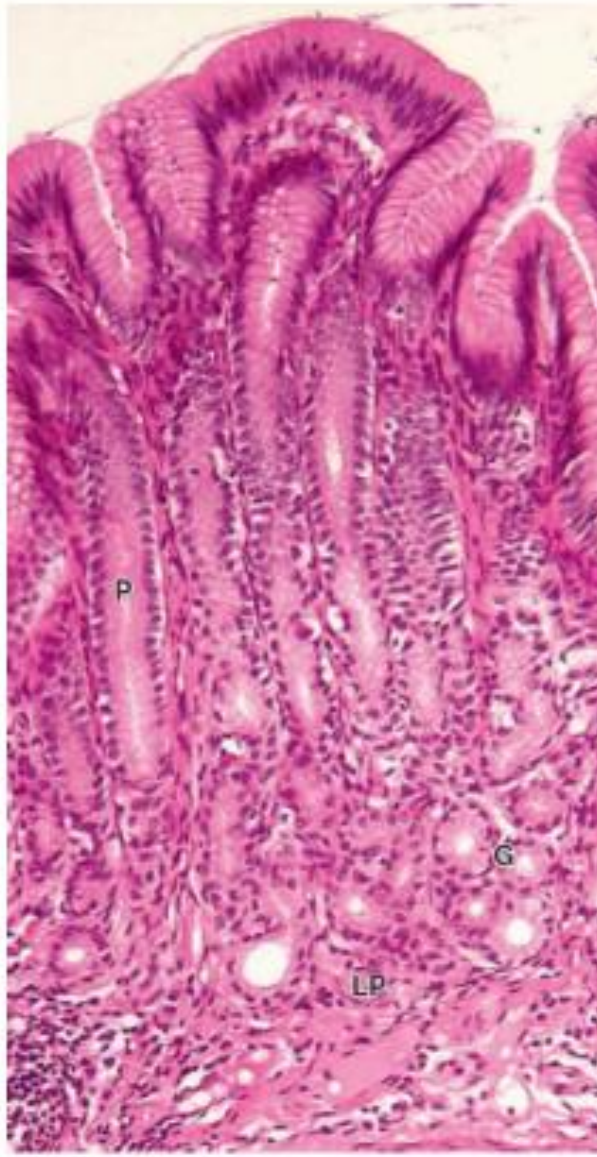

Pylorus:

- The mucosa has deep gastric pits, short, branched coiled tubular pyloric glands.
- They are composed primarily of mucus-secreti cells, a few DNES cells and a few parietal cells.

- The other major layers of the stomach wall are:
- Submucosa:
- Muscularis externa: Composed of three poorly defined layers of smooth muscle; innermost
- , middle circular and outer longitudinal layers.
- Serosa

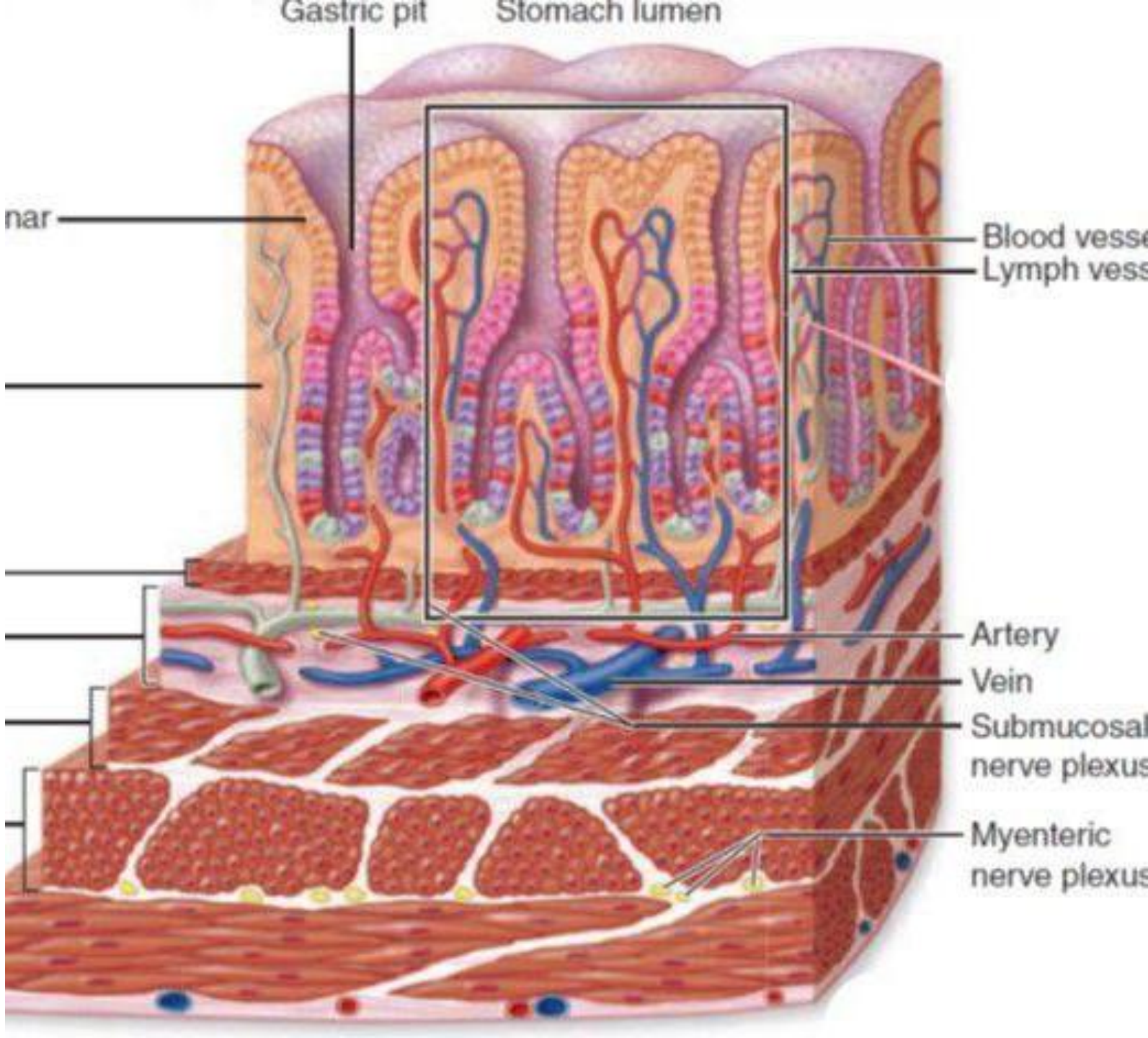

References:

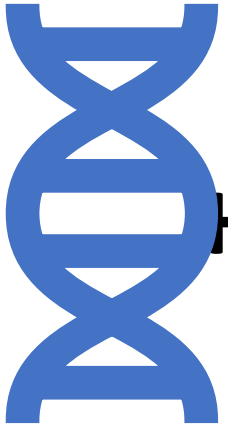

Junqueira's Basic Histology (Text and Atlas) (2018) 15th edition.

Elsevier's Integrated Histology (2007) 1st

Self assessment

1. The chief or peptic (zymogenic) cells of the gastric glands secrete pepsinogen. The latter is converted to pepsin, when the pH in the stomach falls below 5.0.

In the figure below, which of the following arrows point to the location of chief) cells?

a. 1
b. 2
c. 3
d. 4
e. 5

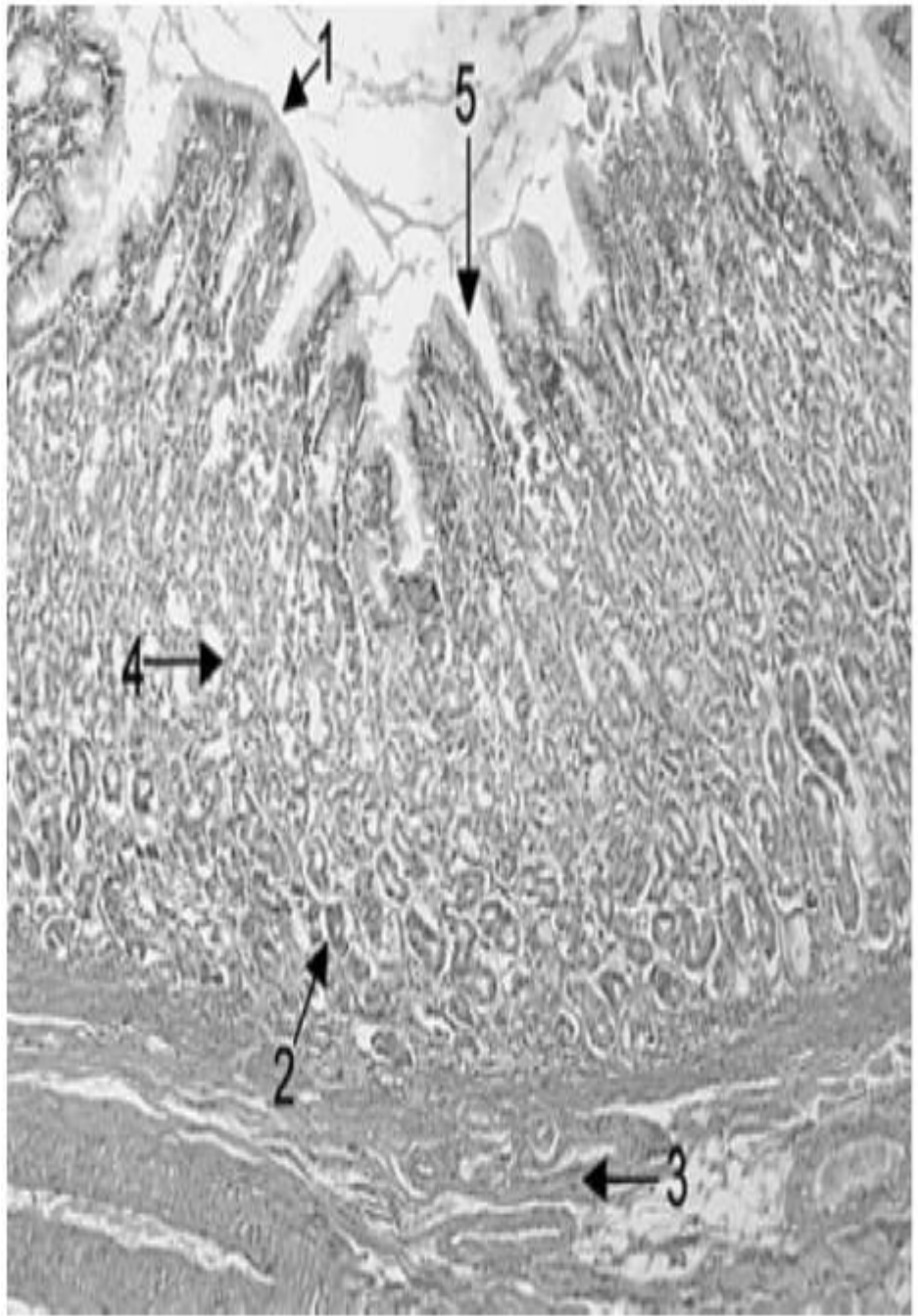

THANK YOU